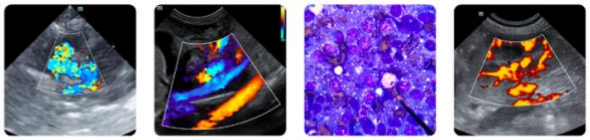

PATIENT
Ena Varela

SPECIES
Canine

BREED
Mixed

SEX
Spayed Female

AGE
16 Years

WEIGHT
28.8 pounds

INTERPRETED BY
Tam Mengine, DVM, DABVP (canine/feline practice)

IMAGING PERFORMED BY
Dr. Gabriel Ferrer DVM

HOSPITAL NAME
Pulse Pet Ultrasound Services

REFERRING VET
Dr. Juan Torres

INVOICE
15210

DATE
04/17/26

PRESENTING CLINICAL SIGNS

Px presented asa a referral for an abdominal ultrasound due to elevated hepatic enzyme values. Px originally visited rDVM to check some cutaneous masses and bloodwork was performed. No diarrhea, vomiting, lethargy, or inappetence reported by owner. Px is currently on Amoxicillin and Denamarin.

Abnormal PE/Chem/CBC/UA Results: Bloodwork attached below for your reference

ULTRASONOGRAPHIC EXAMINATION OF THE ABDOMEN

Urinary System

The urinary bladder is moderately distended with anechoic urine, and no luminal sediment is present. The ureteral papillae, trigone and pelvic urethra (visible to 3.0 cm) are of normal appearance, and the ureters are not visible (normal). No masses, calculi or mucosal irregularities are noted.

Both kidneys are hyperechoic and exhibit mildly decreased cortico-medullary differentiation. There is mild pyelectasia present in the left kidney, with anechoic contents, measuring 3.1 mm in the transverse plane. There is trace pyelectasia present in the right kidney with anechoic contents, The renal pelvic fat is of normal echogenicity. There is no evidence of nephrolithiasis, mineralization, or hydronephrosis. The proximal ureters are not visible (normal). The left kidney is 4.7 cm in length. The right kidney is 5.0 cm in length.

Adrenal Glands

The adrenal glands are both identified in their normal locations. There is a heterogeneous mass arising from the cranial pole of the left adrenal gland, measuring 2.0 cm x 1.7 cm. Vascular invasion is not evident. They are otherwise normal in size and shape with appropriate parenchymal echogenicity and normal phrenic vasculature. The left adrenal gland height is 4.9 mm at the cranial pole and 5.2 mm at the caudal pole. The right adrenal gland height is 1.7 mm at the cranial pole and 6.8 mm at the caudal pole

Spleen

There are multiple hyperechoic masses within the splenic parenchyma, with no visible deviation of the splenic capsule. There is a 1.5 cm by 1.2 cm heterogeneous mass arising from the body of the spleen. The surrounding omental fat is normal. The splenic vasculature is normal with no evidence of congestion or thrombosis, and blood flow through the splenic hilus appears normal.

Liver

The liver is diffusely hyperechoic and subjectively enlarged. There is a 7.1 cm x 6.4 cm heterogeneous mass located in the left cranial aspect of the liver. The surrounding omentum is normal. The portal and hepatic vasculature are of normal size and appearance with no evidence of congestion or thrombosis.

The gallbladder is moderately distended with anechoic contents and a small amount of freely moveable echogenic sludge. The wall was thin and continuous with no focal lesions. The cystic and common bile ducts are normal / not visible.

Gastrointestinal

The stomach is mildly distended with gas. The gastric wall is 4.2 mm with normal deviations due to rugal folds and exhibits appropriate wall layering. The pylorus is of normal appearance.

PATIENT
Ena Varela

SPECIES
Canine

BREED
Mixed

SEX
Spayed Female

AGE
16 Years

WEIGHT
28.8 pounds

INTERPRETED BY
Tam Mengine, DVM, DABVP (canine/feline practice)

IMAGING PERFORMED BY
Dr. Gabriel Ferrer DVM

HOSPITAL NAME
Pulse Pet Ultrasound Services

REFERRING VET
Dr. Juan Torres

INVOICE
15210

DATE
04/17/26

The visualized portions of the duodenum, jejunum, and ileum are of normal thickness with intact wall layering that exhibits the appropriate 1:3 muscularis to mucosa ratio. Intestinal motility appears normal. The duodenum wall measured 5.3 mm wall width. The jejunum wall measured 4.4 mm wall width.

The visible portions of the colon (1.7 mm) are of normal thickness with intact wall layering. The ileocecal junction is normal.

Pancreas

Both limbs of the pancreas is hypoechoic to the surrounding mesenteric fat, with an inhomogenous parenchyma and normal capsular appearance. There is no evidence of peripancreatic inflammation. The pancreatic duct appears normal.

Free Abdomen

There is no evidence of free fluid within the peritoneal cavity. The omentum and intra-abdominal fat are of appropriate echogenicity. Enlarged abdominal lymph nodes are not observed. The aortic trifurcation has normal blood flow with no evidence of thrombosis.

PRIMARY FINDINGS

- Large mass in the left liver.
- Right adrenal mass without evidence of vascular invasion.
- Small splenic mass.

SECONDARY FINDINGS

- Bilateral chronic renal changes.
- Mottled pancreas, consistent with chronic remodeling, which is likely incidental in the absence of symptoms of pancreatitis.

INTERPRETATION OF THE FINDINGS & FURTHER RECOMMENDATIONS

The mass in the liver could represent neoplasia, such as a carcinoma, or a benign hepatoma. The diffusely hypoechoic parenchyma throughout the rest of the liver is typical of a benign reactive hepatopathy, though biopsy would be needed to confirm this. Recommendations include:

❖ Laparoscopic biopsy or ultrasound-guided biopsy for definitive diagnosis. Alternately, fine needle aspirate could be performed for cytology but may not be diagnostic as compared to biopsy.

❖ An abdominal exploratory could be considered as an alternative to biopsy, to attempt to remove the mass *en bloc* as part of a liver lobectomy. Pre-operative CT may be helpful in confirming the mass can be reasonably resected in its entirety.

❖ 3-view chest radiographs

The adrenal mass could represent a pheochromocytoma, adrenal adenocarcinoma, or less likely a benign adenoma. In the absence of symptoms of Cushing's disease, adrenal dependent hyperadrenocorticism is deemed unlikely. Additional recommendations include:

❖ blood pressure measurement to screen for pheochromocytoma

PATIENT

Ena Varela

SPECIES

Canine

BREED

Mixed

SEX

Spayed Female

AGE

16 Years

WEIGHT

28.8 pounds

INTERPRETED BY

Tam Mengine, DVM, DABVP (canine/feline practice)

IMAGING PERFORMED BY

Dr. Gabriel Ferrer DVM

HOSPITAL NAME

Pulse Pet Ultrasound Services

REFERRING VET

Dr. Juan Torres

INVOICE

15210

DATE

04/17/26

- if signs of Cushing's disease are present, then adrenal function testing (either a low-dose dex-suppression test or ACTH stimulation test) is recommended. If no symptoms of Cushing's are present, testing for Cushing's disease would not be recommended.
- measurement of urine catecholamine metabolites can help to identify a pheochromocytoma. Availability of this testing has been variable but may currently be available from Marshfield Laboratories or Idexx Laboratories.
- fine needle aspiration with a 25G needle could be considered if a coagulation profile is normal, depending on clinician comfort level.
- further assessment via CT scan would also be warranted, especially if adrenalectomy is a consideration.

The splenic mass may represent a metastatic lesion from the liver mass, or possibly its own entity. Fine needle aspiration with a 25-gauge needle could be attempted for definitive diagnosis. However, surgical biopsy may be needed, as splenic mass aspirates are often non-diagnostic.

The changes in the kidneys are consistent with chronic renal disease. Findings should be correlated with laboratory values, IRIS staging and clinical signs.

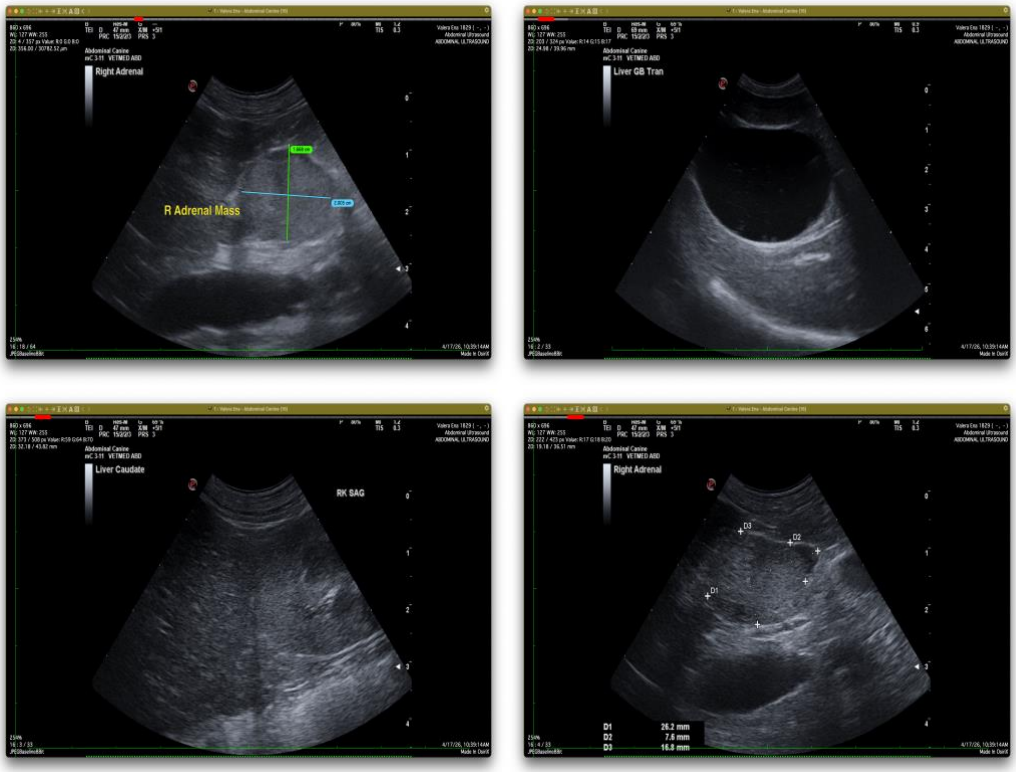

SonoPath
FOSTERING THE ART OF VETERINARY MEDICINE™

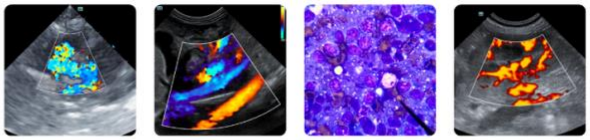

Clinical Sonography & Telecytology
Educational Teleconsultation Services™

SonoPath.com info@sonopath.com 1.800.838.4268

PATIENT

Ena Varela

SPECIES

Canine

BREED

Mixed

SEX

Spayed Female

AGE

16 Years

WEIGHT

28.8 pounds

INTERPRETED BY

Tam Mengine, DVM, DABVP (canine/feline practice)

IMAGING PERFORMED BY

Dr. Gabriel Ferrer DVM

HOSPITAL NAME

Pulse Pet Ultrasound Services

REFERRING VET

Dr. Juan Torres

INVOICE

15210

DATE

04/17/26

The information and recommendations provided are based on the images presented by the referring veterinarian/sonographer. No evaluation can be communicated regarding pathology that was not visible in the image/video clips provided.

Thank you for this referral. If the clinical or image interpretation does not parallel your findings or if I can be of any further assistance, please contact me.

Tam Mengine, DVM, DABVP (canine/feline practice)

info@SonoPath.com